

PLANCHE ANATOMIQUE DE FACE

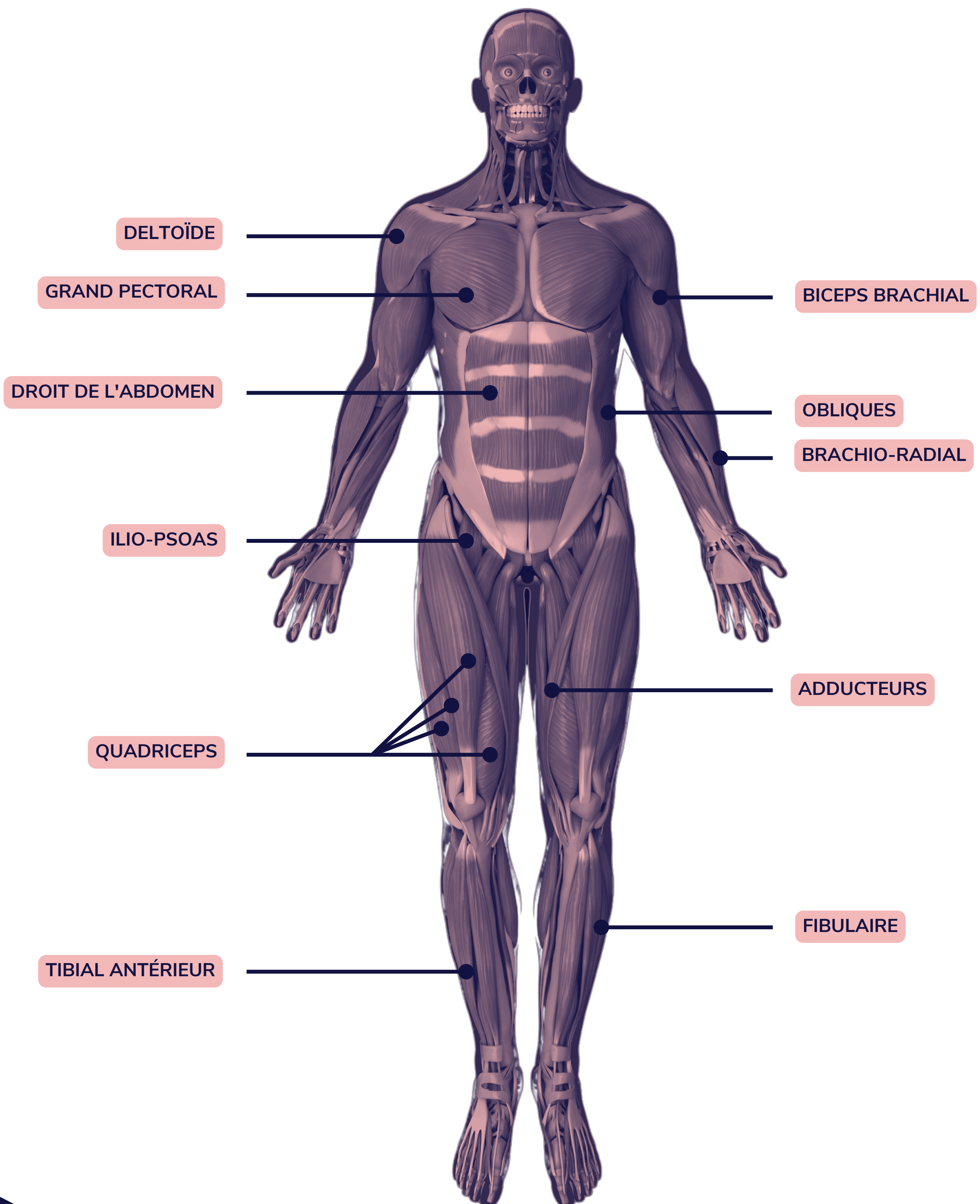
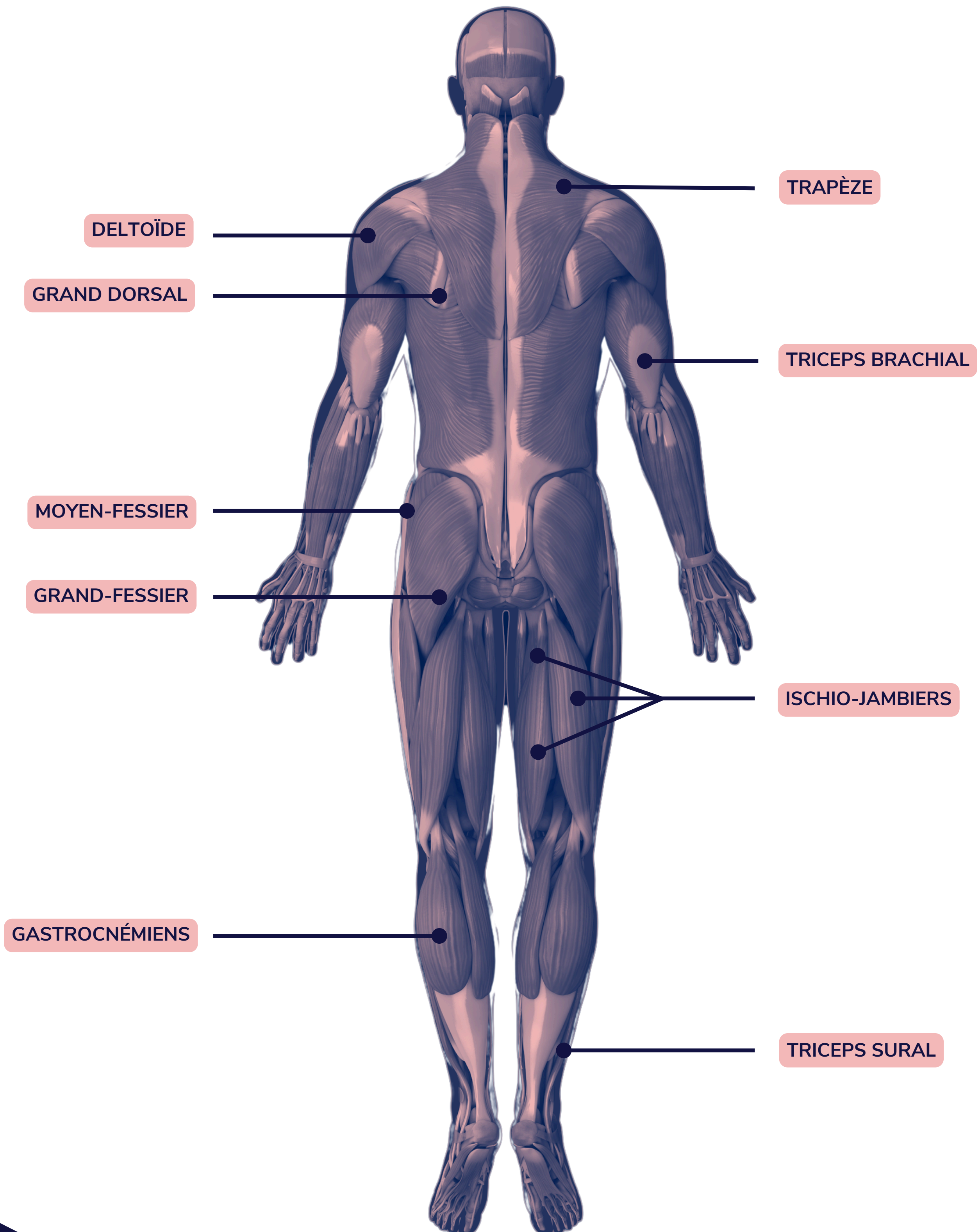
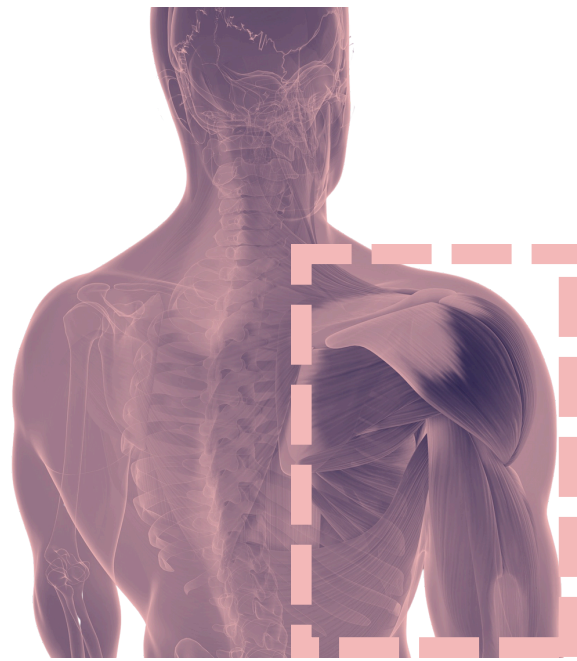

PLANCHE ANATOMIQUE DE DOS

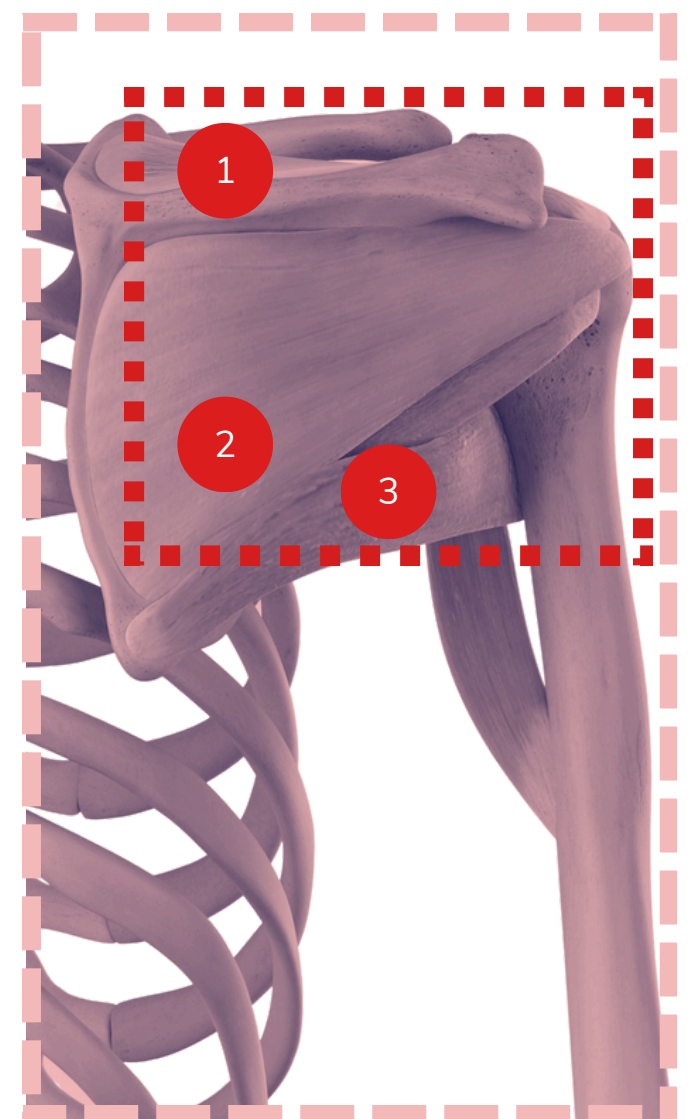
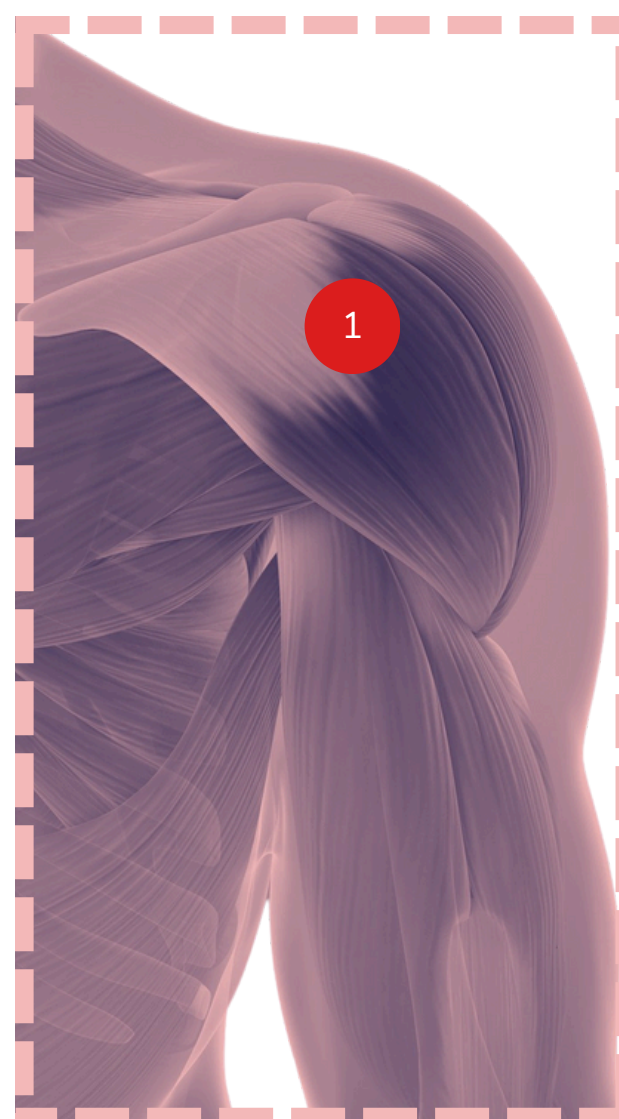
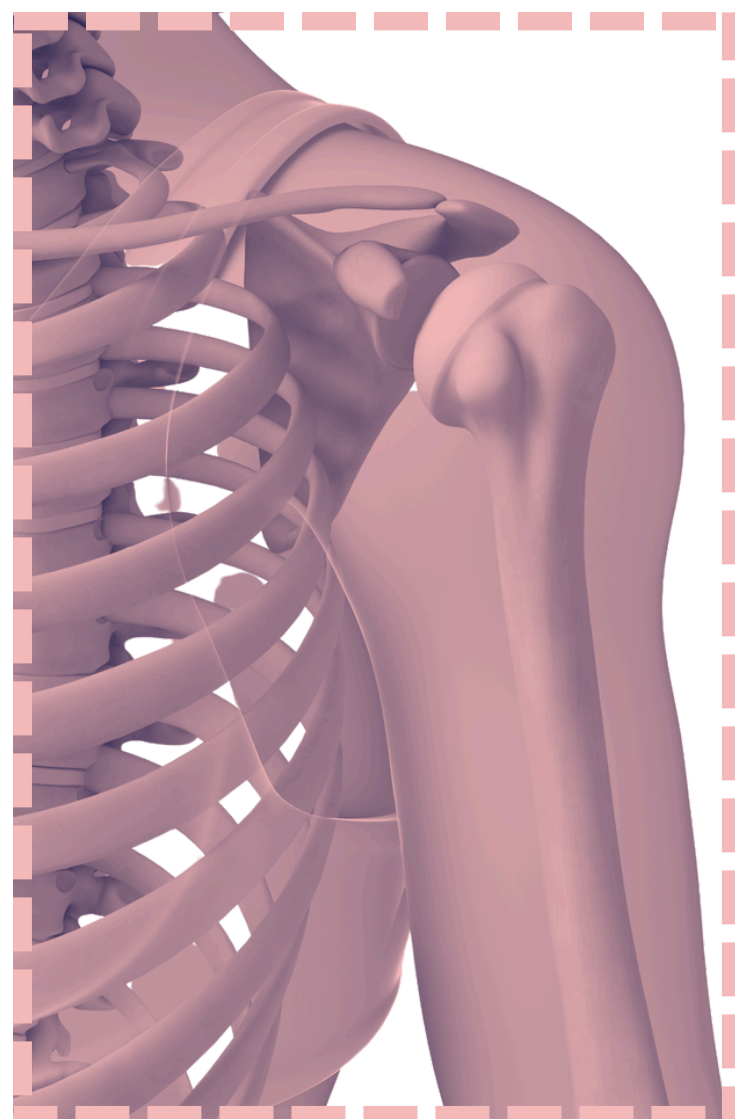


ÉPAULE



ANTÉRIEUR (DE FACE)

POSTÉRIEUR (DE DOS)



1 DELTOÏDE ANTÉRIEUR

2 DELTOÏDE MOYEN

1 SUBSCAPULAIRE

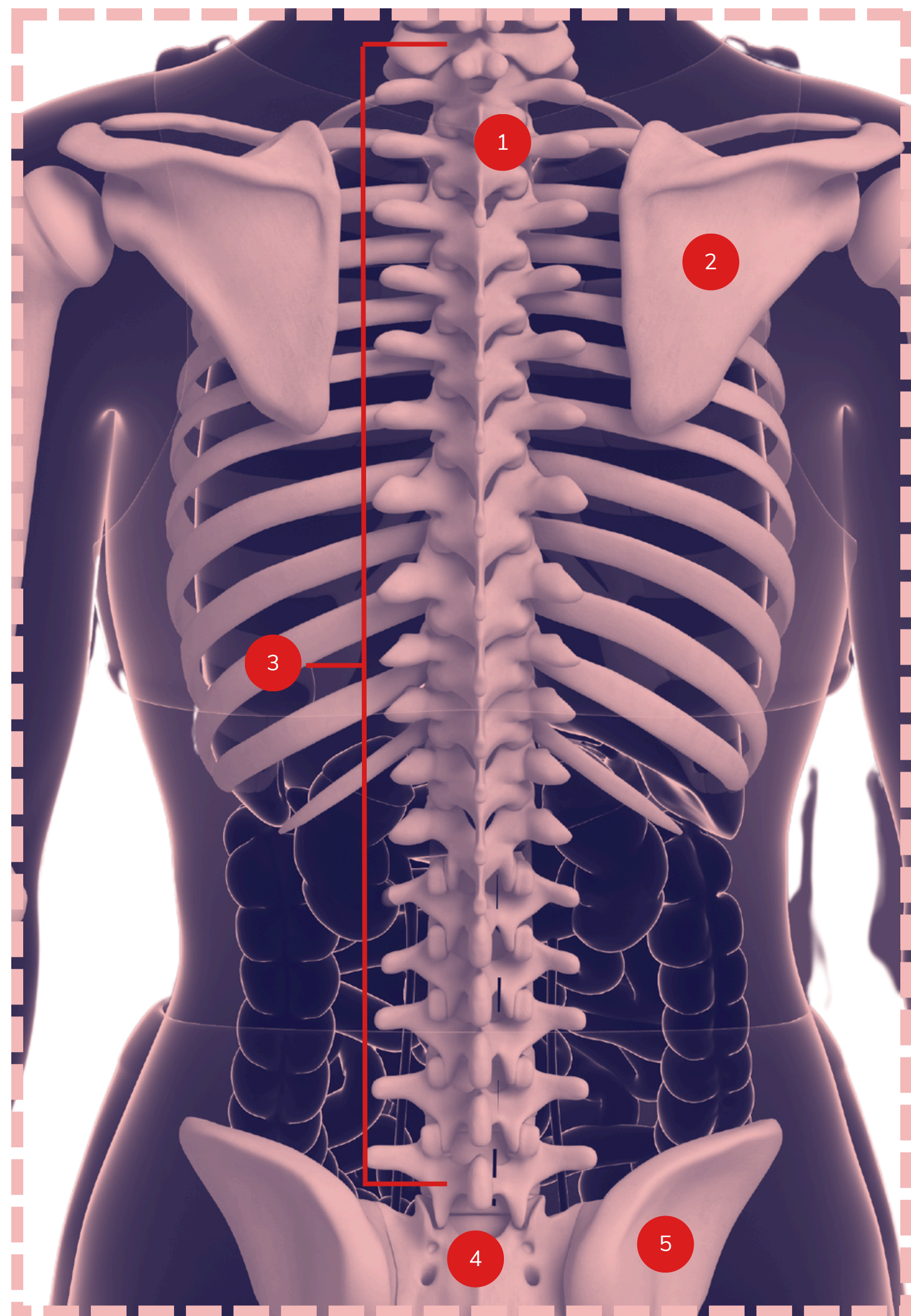
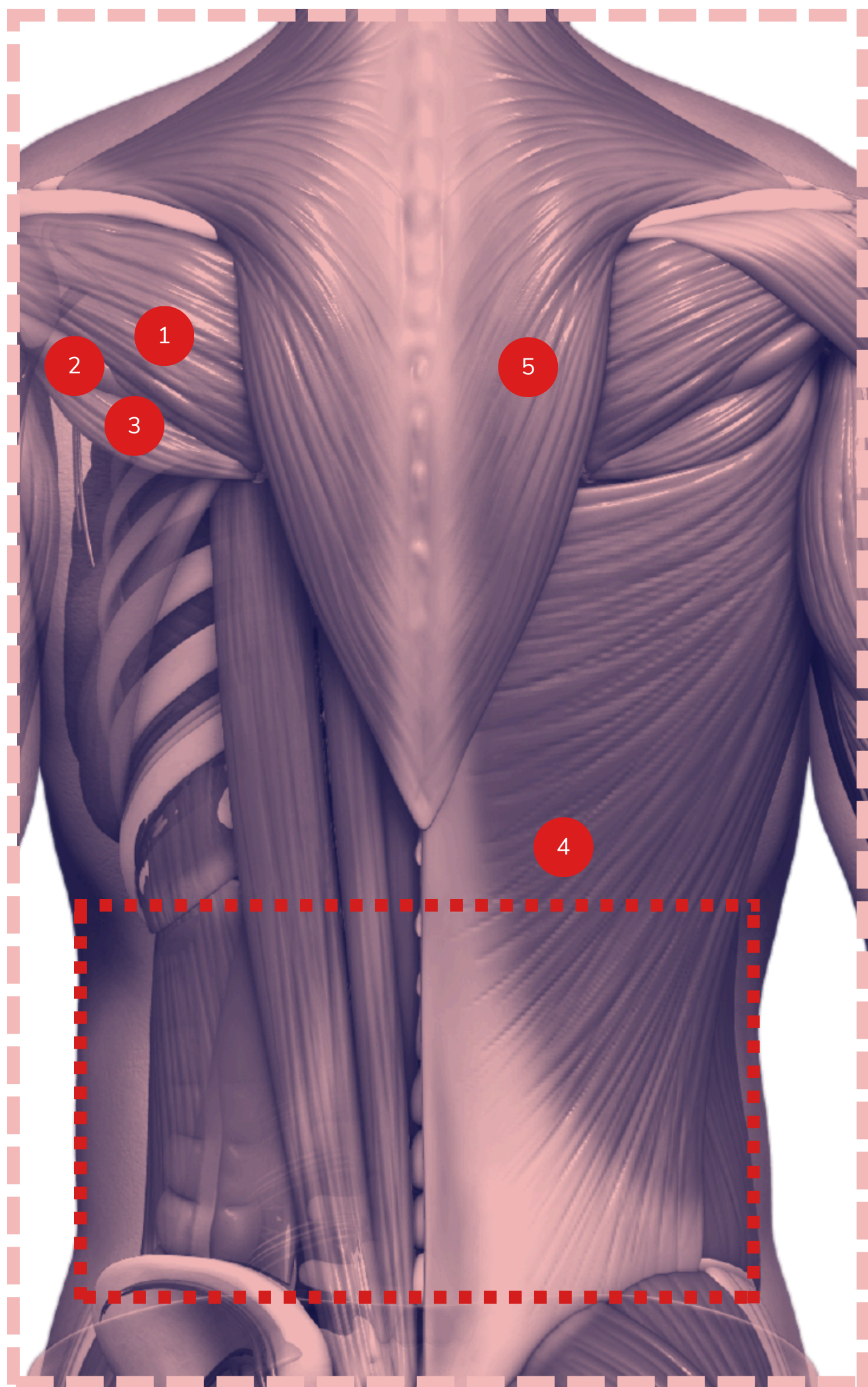
 COIFFE DES ROTATEURS


1 SUPRA-ÉPINEUX

2 INFRA-ÉPINEUX

3 PETIT ROND

DOS




- 1 INFRA-ÉPINEUX
- 2 PETIT ROND
- 3 GRAND ROND
- 4 GRAND DORSAL
- 5 TRAPÈZE
-  LOMBAIRES

- 1 VERTÈBRE
- 2 SCAPULA
- 3 COLONNE VERTÉBRALE
- 4 SACRUM
- 5 OS ILIAQUE

GENOU

CÔTÉ DROIT

ISCHIO-
JAMBIERS

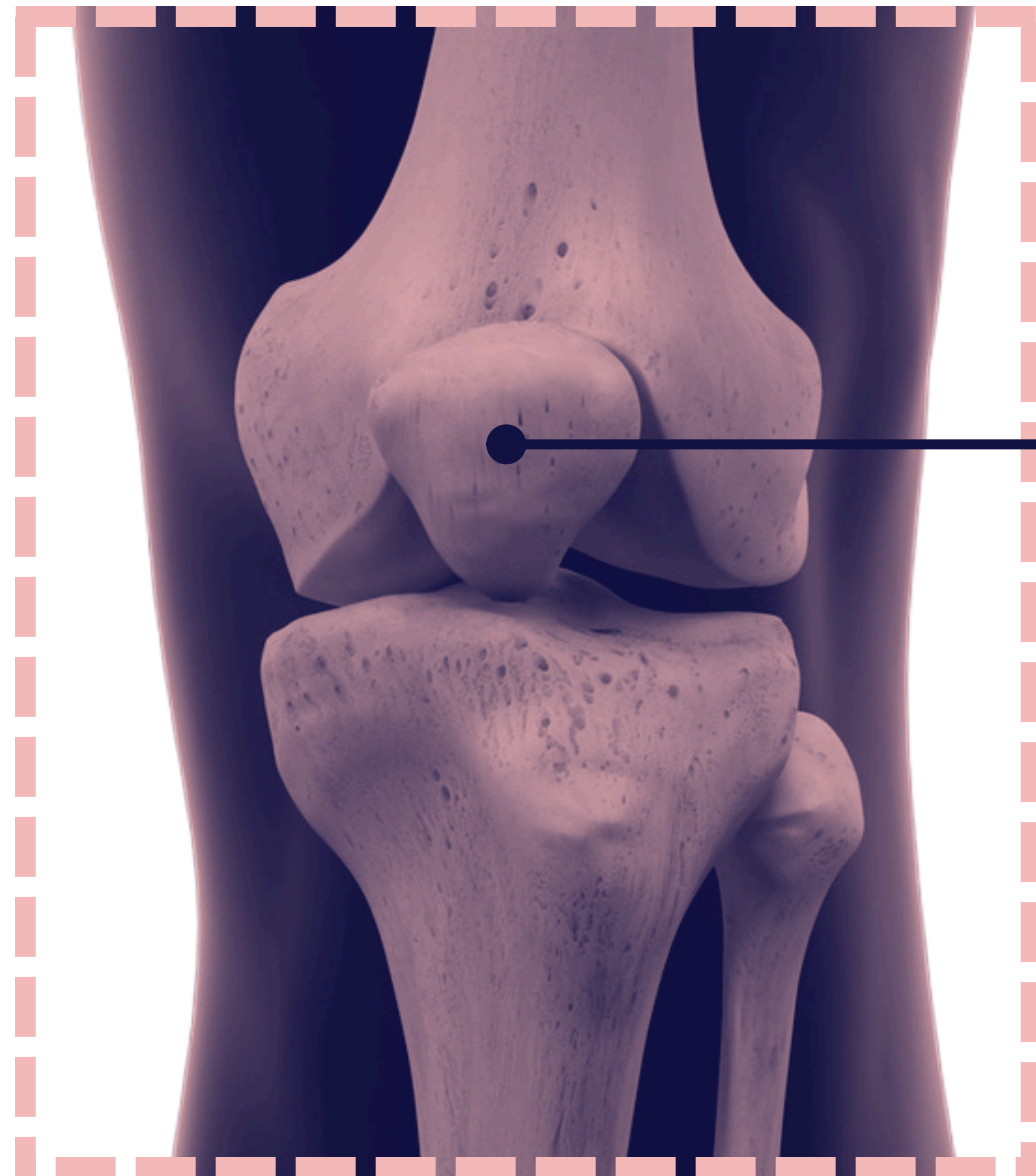


TRICEPS
SURAL



ANTÉRIEUR (DE FACE)

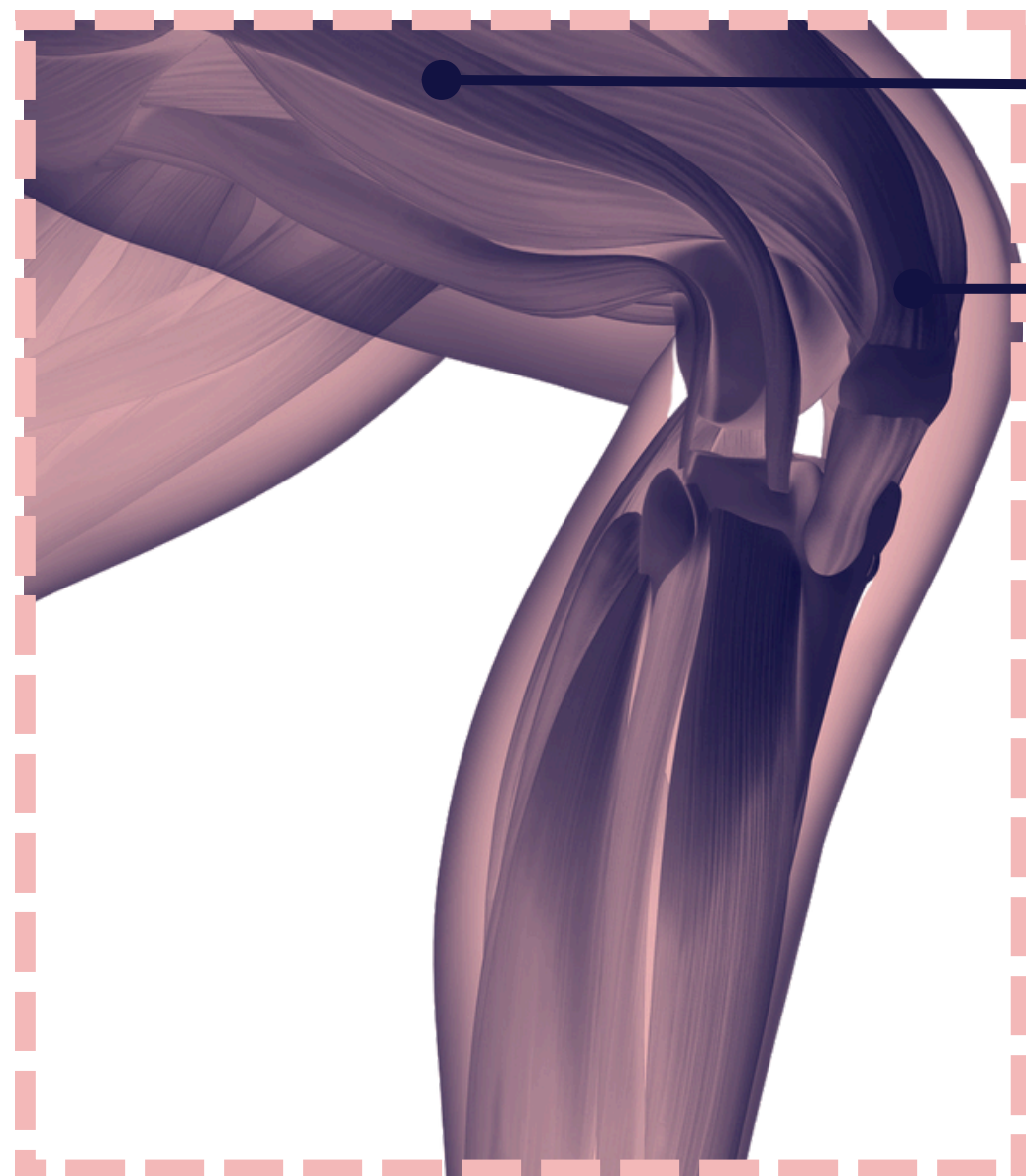
ROTULE



CÔTÉ DROIT

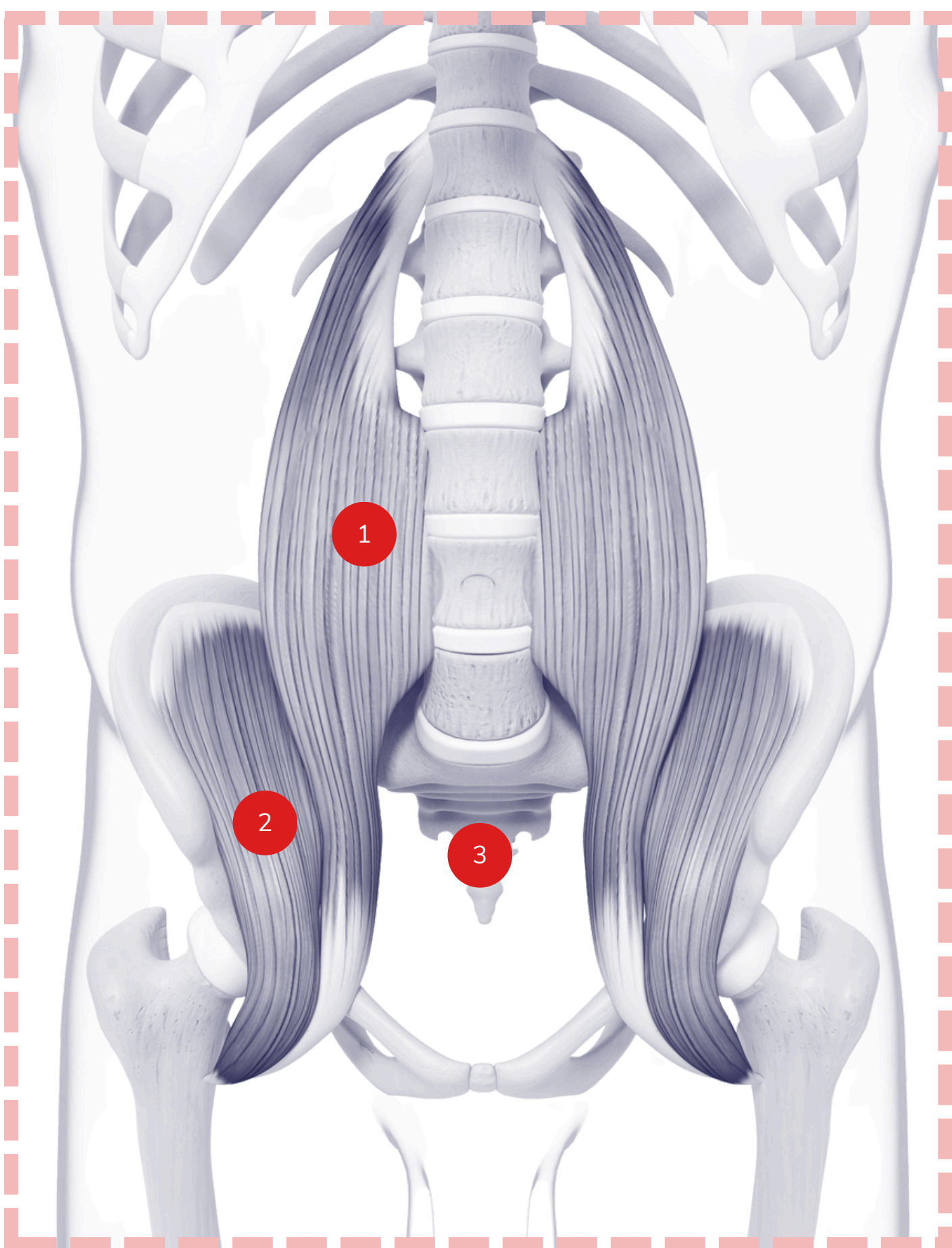
TENSEUR DU
FASCIA LATA

QUADRICEPS



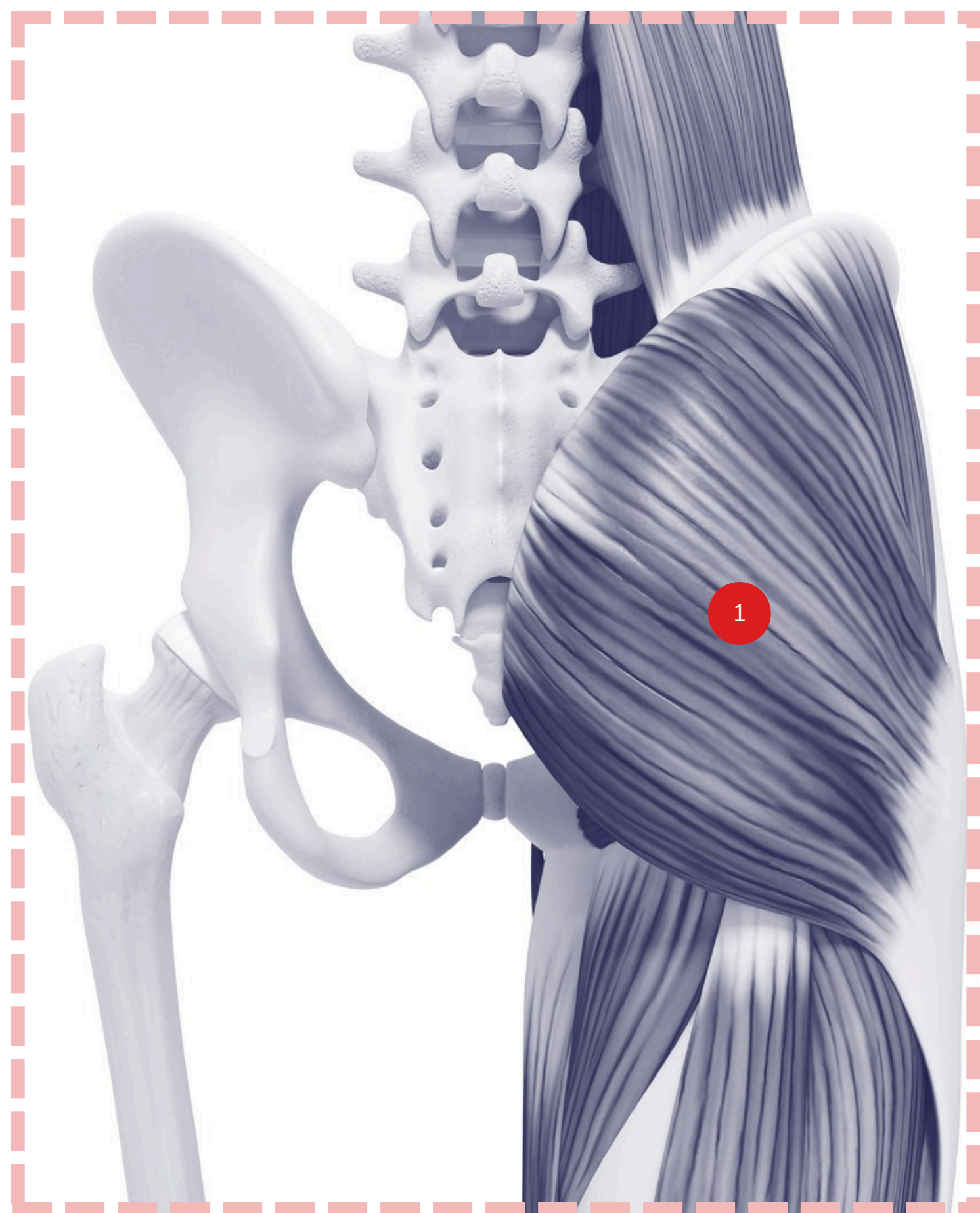
BASSIN

ANTÉRIEUR (DE FACE)



- 1** PSOAS
- 2** ILIAQUE
- 3** COCCYX

POSTÉRIEUR (DE DOS)



- 1** GRAND FESSIER